

# OCCLUSAL EQUILIBRATION IN A PATIENT WITH PAINFUL TMD AFTER ORTHODONTIC TREATMENT-CASE REPORT

<sup>1</sup>Aleksandra Nitecka-Buchta, <sup>1</sup>Elżbieta Tabeńska-Bosakowska, <sup>1</sup>Jolanta Batko-Kapustecka, <sup>2,3</sup>Ewaryst Tkacz, <sup>1</sup>Stefan Baron

<sup>1</sup>Department of Temporomandibular Disorder and Orthodontics, Medical University of Silesia Katowice, pl. Traugutta 2, 41-800 Zabrze Poland, Phone (fax):00-48-323717217, email: dysfunkcje@sum.edu.pl

<sup>2</sup>Institute of Theoretical and Applied Informatics, Polish Academy of Sciences, Bałtycka 5, 44-100 Gliwice, Poland  
Phone:+48322317319, Fax: +48322317026, email: office@iitis.gliwice.pl.

<sup>3</sup>Department of Biomedical Engineering, Faculty of Electrical Engineering and Communication, Brno University of Technology, Technická 12, 61600 Brno, Czech Republic, Phone: +420541141111; email: tkacz@feec.vutbr.cz

**Abstract-** Painful temporomandibular disorders (TMD) can coexist with occlusal disturbances. Our case reports a patient after orthodontic therapy, who was treated with splint therapy first and afterwards with occlusal equilibration, under control of the T-Scan III system. A long term relief was achieved in the reported case.

**Key words:** TMD, splint therapy, occlusal equilibration, system T-Scan III, post orthodontic treatment

## I. INTRODUCTION:

Occlusal disorders can be the reason for and the effect of temporomandibular dysfunction (TMD). Especially when it comes to parafunctions like bruxism. Changes in occlusion can be caused by tooth loss, tooth decay, tooth migration (Godon effect), iatrogenic restorations, prosthetic crowns and bridges or iatrogenic orthodontic treatment. The evocation of TMD by genetic factors has not been proved until now. The ability of adaptation of the stomatognathic system to changes and their compensation is widely discussed in the literature. It has been proven though, that occlusal contacts are of very high importance, especially in patients with centric bruxism (teeth grinding). In physiological conditions occlusal contacts should only occur during swallowing (12-25 min/24h). Disorders, like occlusal disturbances can be the reason for an intensification of occlusal parafunctions in patients with bruxism. A disformation of this statement are patients without a balanced occlusion and without any discomfort of the stomatognathic system. A very important role plays the concept of adaptation, the ability to adjust. Adaptation is the ability to adjust to changes each individual undergoes during their life after completed development and tissue differentiation. This changes are based on the modification of structure or function of the stomatognathic system. The ability of adjustment determines the efficiency of adaptation. This phenomenon occurs under influence of permanently changed anatomical conditions and/or external stress. The process of adaptation has to be distinguished from the individual personal evaluation. Further it is important to understand that occlusal modulations (in the stomatognathic system) do not always guarantee ideal functional conditions<sup>1,2</sup>.

This study is a case report of a 24 year old patient after orthodontic treatment with an orthodontic appliance. The treatment was finished when the patient reached the age of 14. When stress causing situations started to occur (university), dysfunction of the stomatognathic system started to manifest.

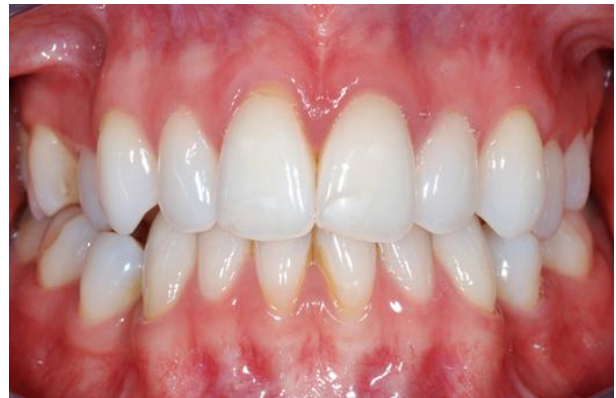

Fig.1:The patients occlusion-photograph taken during the first examination

## II. MEDICAL INTERVIEW:

The patient complained about idiopathic headaches localized in the region of her forehead and temple on the left side. The patient described the pain as dull with diffused localization and medium intensity (VAS=4). According to the patient the duration of the pain was long, lasting mostly the whole day. The patients first visit in the TMD-Clinic at the Silesian Medical University Zabrze was in March 2013, caused by a 6 month period of intensive pain.

### Publication History

Manuscript Received : 5 August 2014  
Manuscript Accepted : 20 August 2014  
Revision Received : 22 August 2014  
Manuscript Published : 31 August 2014

### III. MATERIAL AND METHODS:

#### 1. Medical examination:

During abduction of the mandible clicking and popping sounds of the left TMJ occurred, especially in the intermediate phase of abduction. Palpation of the left TMJ during abduction was painful. The range of abduction of the mandible was not limited. Left sided deviation occurred in the intermediate phase of abduction with return to symmetry at maximal abduction. An X-ray of the left and right TMJ in maximal intercuspitation and maximal abduction was made. No structural and spacial abnormalities of the condyles could be found.

The patient did not relate any tooth sensitivity to cold or sour food, nor did she experience gum bleeding during brushing her teeth or in the morning after waking up. The patient though did notice weariness of the masticatory and neck muscles in the morning after waking up and in the evening. She also reported that she is clenching her teeth together during daytime (centric bruxism). The patient never experienced limited mouth opening and never noticed tooth grinding.

#### 2. Occlusion:

The intraoral examination showed canini and molar Angle class I on the right and on the left side and crossbite of the first right premolar (Fig.1). The lack of four premolars suggest earlier orthodontic treatment with extraction therapy. Further the examination showed, that lower molars were inclined lingual and the presence of premature contacts right and left lower second molars (Fig.2). The first and second lower incisors showed gingiva recessions. The occlusal contacts were diagnosed with the T-Scan III System before treatment (Fig.3,4).

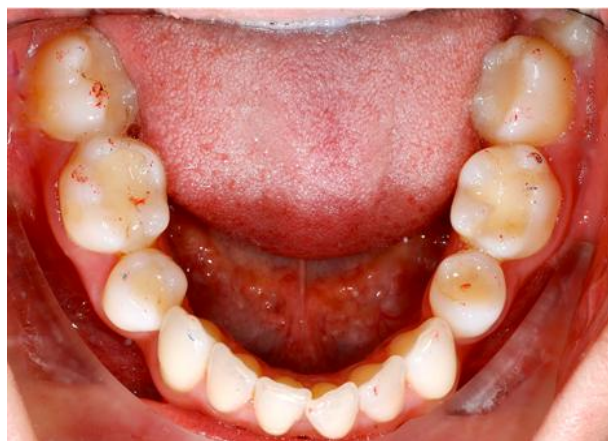

Fig.2:Premature contacts on the left and right lower second molar

The occlusal diagnosis with the T-Scan was repeated during and after the treatment with correction of occlusal contacts. During this diagnosis occlusal contacts, their changes during maximal intercuspitation and the equilibration of the masticatory muscles were controlled. A similar technique of occlusal equilibration in the treatment of myofascial pain was performed by Kerstein<sup>3,4,5</sup>.

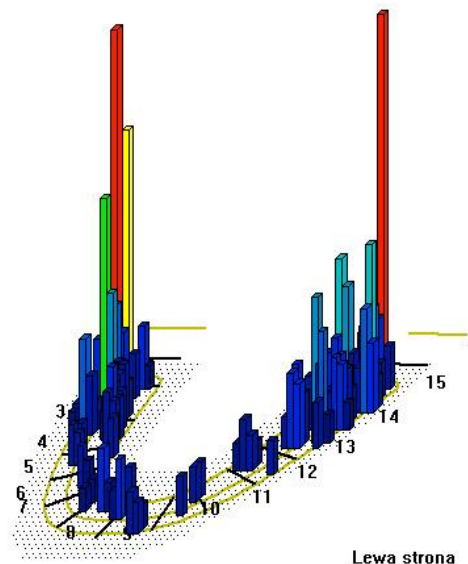


Fig.3:T-Scan image before correction of occlusal contacts - intensive occlusal contacts in region of the left and right lower second molar

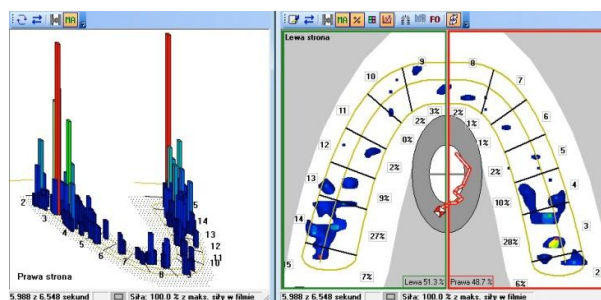


Fig.4:T-Scan image before occlusal correction- prevalence of contacts on the right side

The T-Scan image before occlusal correction shows the lack of occlusal balance and a translation of the centre of force to the right. The reason for this might be premature contacts or a restricted glide between the centre of occlusion and centric relation. Both this factors can aggravate parafunctional activity (Fig.4).

#### 3. Masticatory muscle examination:

During examination of the masticatory muscles moderately pain of the right masseter, musculus pterygoideus lateralis and medialis and neck muscles on the right side occurred. On the left hand side the pain was stronger. The patient felt pain of the left masseter, left musculus pterygoideus lateralis and medialis during palpation of these muscles.

Visual analogue scale (VAS): The patient marked her level of pain on a 10-mm line as a VAS=4.

#### 4. Diagnose:

The patient was diagnosed with myofascial pain with referral – DC-TMD 1b<sup>6</sup> and headaches – ICHD-III 11.7<sup>7</sup>, i.e. secondary pain caused by dysfunction of the stomatognathic system.

#### 5. Therapy:

##### I. Patient education:

The patient was educated about the necessity of stopping the parafunctional habits affecting her stomatognathic system, like teeth grinding during daytime. Self-control and muscle relaxation through physiotherapy were recommended, especially exercise of the antagonistic muscles. The patient was asked to make notes of the quantity and quality of her pain, in order to control the effects of the treatment.

##### II. Physiotherapy:

Until the handover of the oral appliance the patient was told to relax her masticatory muscles by warm dressings, exercise, muscle stretching and self-control (control of tooth grinding). No pharmaceuticals were applied. Massage and physiotherapy have proven to be a very effective treatment in TMD muscle soreness<sup>8</sup>.

##### III. Splint therapy:

The patient was treated with a flat oral appliance (Ercodur modified with acryl) with adjusted regular occlusal contacts on the overall surface of the splint in static occlusion and with canini/incisor guidance (Fig.5,6,7).

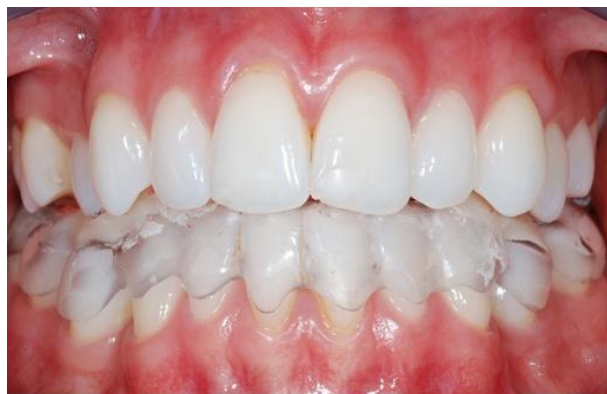

Fig.5:The occlusal appliance in situ

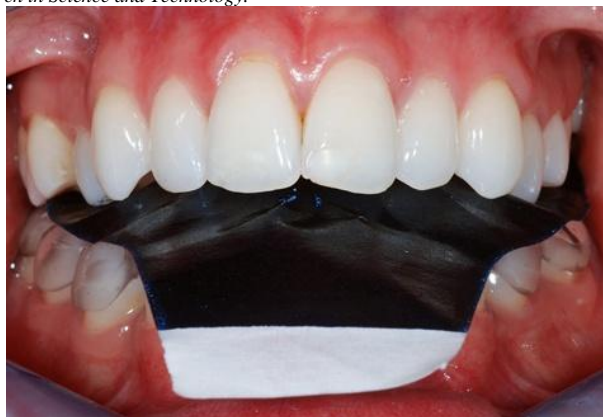

Fig.6:Control of occlusal contacts with use of articulating paper

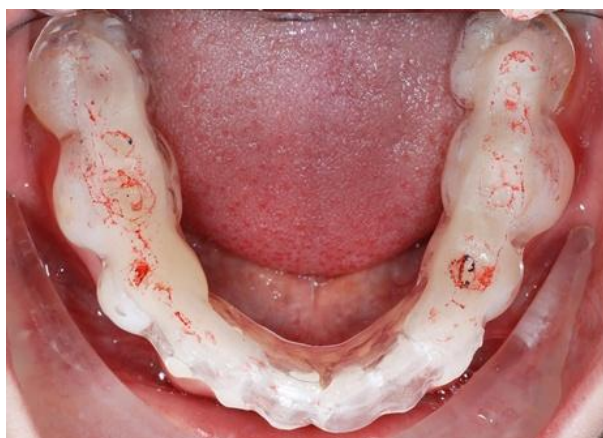

Fig.7:Occlusal contacts on the adjusted appliance- with canini guidance

A reduction of the pain that was satisfying was maintained after 2 weeks of using the oral appliance. The effect was though minimized to a few hours after wearing the appliance. Because of the patients pathological occlusion, pain still occurred at the end of the day, even though the intensity of pain was minimized. In a short period of time without the appliance both the quantity and the quality of the pain rose again. The patient was informed that there is a medical necessity for a repeated orthodontic treatment, which she did not agree to. Also the still in the evening occurring pain excluded a causative treatment at this point of time.

The aetiology of TMD is multicausal and symptoms do not occur in every patient with occlusal disturbances. The first goal of treatment is always to eliminate the pain. Further steps are depended on indications, treatment possibilities and patient will.

**IV. Occlusal equilibration, elimination of occlusal disturbances:**

After two weeks of splint therapy treatment the patient revealed reduction in muscle tension and analgesic effect. Occlusal equilibration was performed after two weeks of myorelaxation- occlusal disturbances were eliminated. System T-Scan III was used to establish proper occlusion and remove parafunctional contacts by selective 36, 37, 47 enamel removal (Fig.8, Fig. 10).

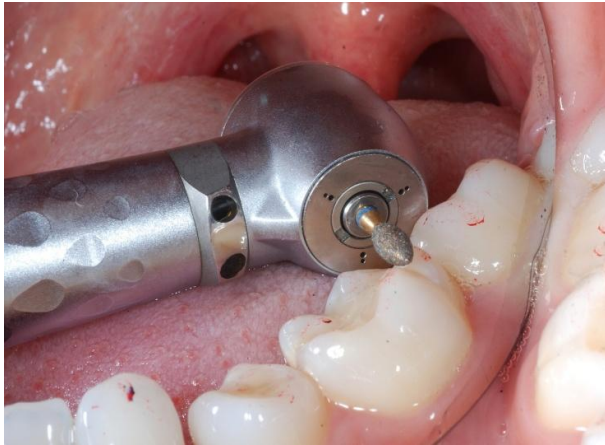

Fig.8:Correction of premature contacts- lower left first and second molars

The procedure was performed with a high-speed turbine, water sprayed, with diamond burs. The absolute minimal amount of hard tissues was removed. After occlusal equilibration a protective varnish with fluoride was used to protect the hard tissues of the tooth. The patient was also educated to use a toothpaste with high concentration of fluoride. System T-Scan III was used to visualize proper occlusal contacts, and to preserve balanced occlusion (Fig.9, Fig.11, Fig.12).

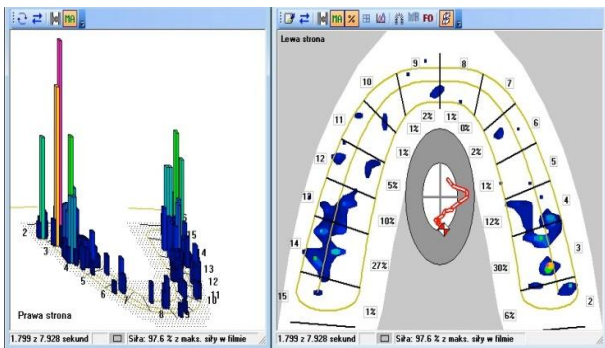


Fig.9:T-Scan image after occlusal correction on the left side

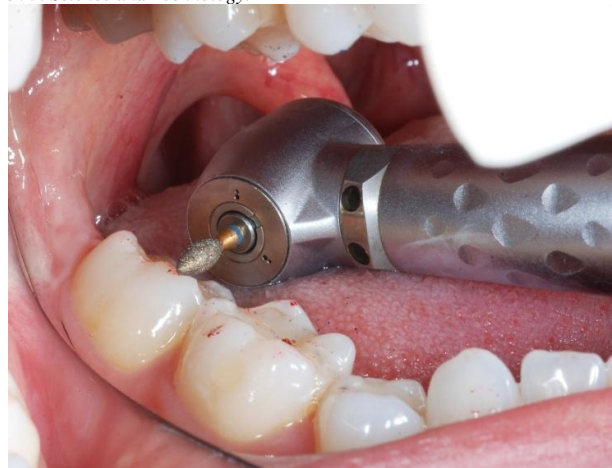

Fig.10:Occlusal correction: lower left second molar

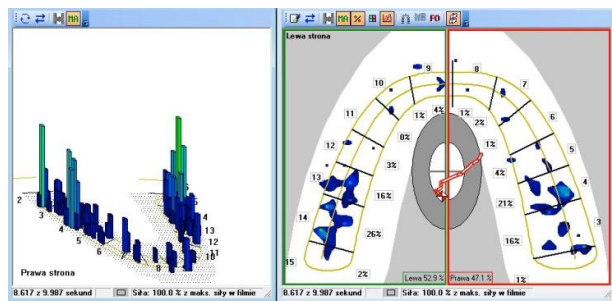
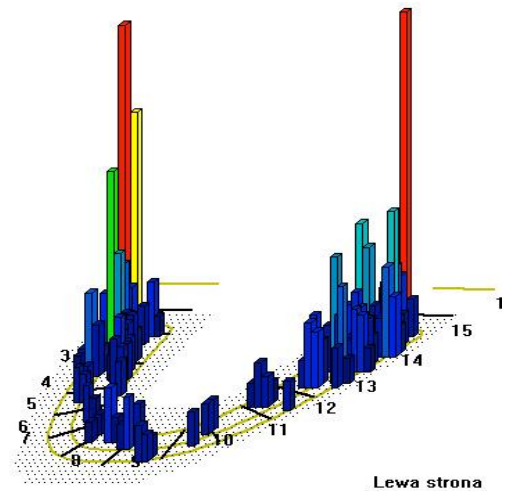


Fig.11:T-Scan image after bilateral occlusal correction of the lower left first and second molar and lower right first molar.. Lack of occlusal disturbances and centralisation of the centre of maximal bite force. Reduction of disturbances in centric glide.



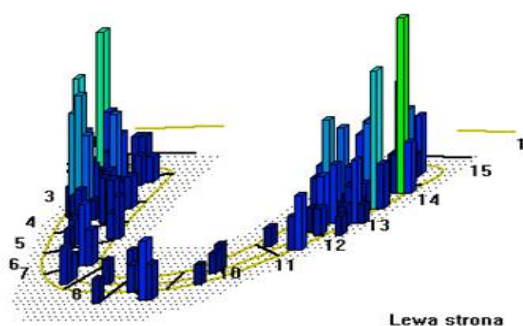


Fig.12:T-Scan image after bilateral correction of occlusal contacts: upper picture before correction, lower picture after occlusal correction

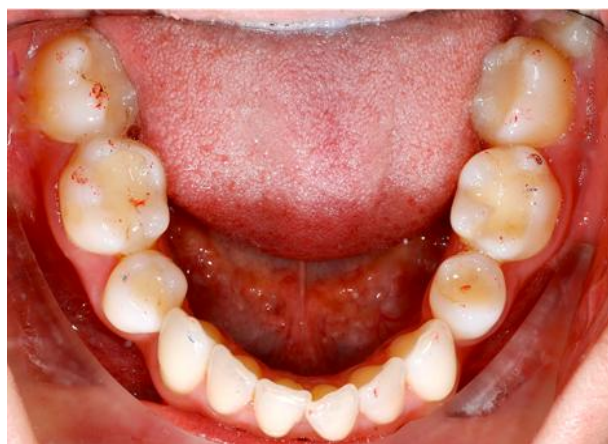

Fig.13:Intraoral picture before correction of occlusal contacts

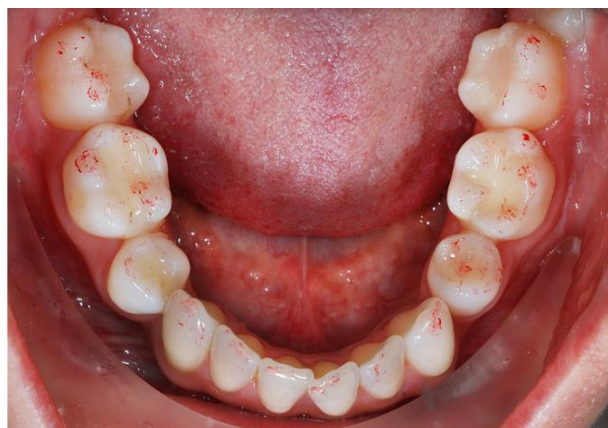

Fig.14:Intraoral picture after correction of occlusal contacts

After occlusal equilibration a permanent and significant relief was achieved, the intensity of pain in VAS scale was VAS=1. Achieved occlusion was close to ideal balanced occlusal contacts (Fig.13,14). The patient released a huge relief in pain symptoms. The clinical improvement allowed the consideration of orthodontic treatment. Before this

improvement, orthodontic treatment was impossible to perform, because of the pain symptoms. In case of no further orthodontic treatment (decision of patient), an orthodontic retainer or Ercodur splint is necessary, to prevent further occlusal changes.

## DISCUSSION:

### Is occlusal equilibration a therapy?

It is not always easy for a dentist to choose which kind of therapy would be the most beneficial for a patient. Reduction of painful symptoms is always reasonable. In our case a young woman (24) could not afford and did not want to perform orthodontic treatment with permanent braces. Pain remission was only temporary, and after all day parafunctional activity a patient felt muscle soreness in the evening. The patient could not control teeth clenching and grinding- day bruxism. Muscle soreness and temporary pain relief was a reason for a permanent, selective teeth preparation- occlusal equilibration with T-Scan III System. Irreversible treatment methods with reduction of tooth hard tissues in patients with TMD are acceptable only in adults in similar clinical situation, especially after orthodontic therapy.

The authors believe that orthodontic treatment unfolds differently in children and in adults. In children we can observe far advanced processes of adaptation to the acquired occlusal contacts. In adults it is an absolute necessity to precisely control an occlusion after any intervention in occlusal contacts, especially during and after orthodontic treatment. Interaction between TMD and orthodontics is widely analyzed and many publications are available in that field <sup>9,10,11,12,13,14,15,16,17,18,19,20,21</sup>. This connection is multidimensional and probably statistical evaluation would be impossible to perform. Although in everyday practice we can often observe changes in TMD muscle pain intensity, after occlusal equilibration.

## ACKNOWLEDGMENTS:

This paper has been supported by the Program Project UMO-2012/07/B/ST6/01238 and authors would like to express their appreciation for that. The authors declare that there is no conflict of interests regarding the publication of this paper.

## REFERENCES:

- [1] Biologia. Multimedialna encyklopedia PWN Edycja 2.0. Wrocław: Warszawa : Wydawnictwo Naukowe PWN, 2008. ISBN 978-83-61492-24-5.
- [2] Encyklopedia Biologia. Greg, 2008. ISBN 978-83-7327-756-4.
- [3] Kerstein RB, Farrell S, Treatment of myofascial pain-dysfunction syndrome with occlusal equilibration, J Prosthet Dent. 1990 Jun;63(6):695-700
- [4] Harkins S, Treatment of myofascial pain dysfunction syndrome with occlusal equilibration. J Prosthet Dent. 1991 Jan;65(1):153-4.
- [5] Kerstein RB, Radke J, Masseter and temporalis excursive hyperactivity decreased by measured anterior guidance development., J.Cranio. 2012 Oct;30(4):243-54.
- [6] Schiffman EL, Research Diagnostic Criteria for Temporomandibular Disorders: Future Directions, J Orofac Pain. 2010 Winter; 24(1): 79-88.

- [7] The International Classification of Headache Disorders- ICHD III-3rd edition (beta version) ,Headache Classification Committee of the International Headache Society (IHS): Cephalalgia 33(9): 629–808
- [8] Miernik, Więckiewicz M, Paradowska A., Więckiewicz W. Massage Therapy in Myofascial TMD Pain Management, Adv Clin Exp Med 2012, 21, 5, 681–685
- [9] Leite RA, Rodrigues JF, Sakima MT, Sakima T. Relationship between temporomandibular disorders and orthodontic treatment: a literature review. Dental Press J Orthod. 2013 Jan-Feb;18(1):150-7.
- [10] Henrikson T, Nilner M. Temporomandibular disorders, occlusion and orthodontic treatment. J Orthod. 2003 Jun;30(2):129-37; discussion 127.
- [11] Michelotti A, Iodice G. The role of orthodontics in temporomandibular disorders. J Oral Rehabil. 2010 May;37(6):411-29. doi: 10.1111/j.1365-2842.2010.02087.x. Epub 2010 Apr 9.
- [12] Gebeile-Chauty S, Robin O, Messaoudi Y, Aknin Can orthodontic treatment generate temporomandibular disorders and pain? A review. JJ. Orthod Fr. 2010 Mar;81(1):85-93. doi: 10.1051/orthodfr/2010009. Epub 2010 Apr 1.
- [13] McNamara JA Jr, Seligman DA, Okeson JP. Occlusion, Orthodontic treatment, and temporomandibular disorders: a review. J Orofac Pain. 1995 Winter;9(1):73-90.
- [14] Kanavakis G, Mehta N. The role of occlusal curvatures and maxillary arch dimensions in patients with signs and symptoms of temporomandibular disorders. Angle Orthod. 2013 Mar 19.
- [15] Abrahamsson C, Henrikson T, Nilner M, Sunzel B, Bondemark L, Ekberg EC. TMD before and after correction of dentofacial deformities by orthodontic and orthognathic treatment. Int J Oral Maxillofac Surg. 2013 Jun;42(6):752-8. doi: 10.1016/j.ijom.2012.10.016. Epub 2012 Nov 16.
- [16] Slade GD, Diatchenko L, Ohrbach R, Maixner W. Orthodontic Treatment, Genetic Factors and Risk of Temporomandibular Disorder. Semin Orthod. 2008 Jun;14(2):146-156.
- [17] Akhter R, Hassan NM, Ohkubo R, Tsukazaki T, Aida J, Morita M. The relationship between jaw injury, third molar removal, and orthodontic treatment and TMD symptoms in university students in Japan. Orofac Pain. 2008 Winter;22(1):50-6.
- [18] Tecco S, Teté S, Crincoli V, Festa MA, Festa F. Fixed orthodontic therapy in temporomandibular disorder (TMD) treatment: an alternative to intraoral splint. Cranio. 2010 Jan;28(1):30-42.
- [19] Kümbüloğlu O, Saracoglu A, Bingöl P, Hatipoğlu A, Ozcan M. Clinical study on the comparison of masticatory efficiency and jaw movement before and after temporomandibular disorder treatment. Cranio. 2013 Jul;31(3):190-201.
- [20] Badel T, Marotti M, Pavicin IS, Basić-Kes V. Temporomandibular disorders and occlusion. Acta Clin Croat. 2012 Sep;51(3):419-24.
- [21] Abrahamsson C, Henrikson T, Nilner M, Sunzel B, Bondemark L, Ekberg EC. TMD before and after correction of dentofacial deformities by orthodontic and orthognathic treatment. Int J Oral Maxillofac Surg. 2013 Jun;42(6):752-8. doi: 10.1016/j.ijom.2012.10.016. Epub 2012 Nov 16.